

Maternal and Developmental Toxicity

effects of acute xylene exposure in Sprague Dawley rats

Noor Asyikin Suaidi¹, Siti Rosmani Md Zin^{1*}, See-Ziau Hoe², Mohd Helmy Mokhtar³, Mohammed Abdullah Alshawsh^{4*}

¹Department of Anatomy, Faculty of Medicine, Universiti Malaya, 50603 Kuala Lumpur, Malaysia; ²Department of Physiology, Faculty of Medicine, Universiti Malaya, 50603 Kuala Lumpur, Malaysia;

³Department of Physiology, Faculty of Medicine, Universiti Kebangsaan Malaysia, 56000 Kuala Lumpur, Malaysia; ⁴Department of Pharmacology, Faculty of Medicine, Universiti Malaya, 50603 Kuala Lumpur, Malaysia

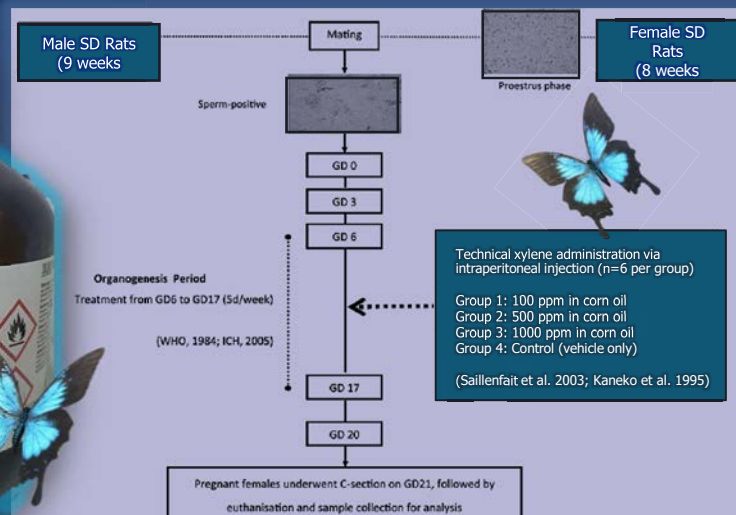
BACKGROUND

Xylene is widely used in medical laboratories and is considered a safe alternative to benzene. Nevertheless, concerns have been raised about the effects of xylene exposure at the ambient level on pregnant lab personnel.

OBJECTIVES

This study aimed to investigate the toxicity effects of xylene on maternal and foetal parameters.

METHODS



1000 ppm-treated group showed a significant ($p < 0.05$) decrease in maternal body weight (BW), corrected weight gain (Figure 1) and food intake, and increased intrauterine deaths (11/277) (Figure 2). All xylene concentrations caused a significant ($p < 0.05$) decrease in the placental weights of the male foetuses. However, only placentae of the 1000 ppm-treated group ($p < 0.01$) were affected in females. Moreover, male and female foetal BW was significantly ($p < 0.01$) reduced in 500 and 1000 ppm-treated groups (Figure 3). This is consistent with an increased count of glycogen cells in placentae of the same groups (Figure 4). Histological examination also revealed marked uterine inflammation and necrosis in the xylene-exposed dams (Figure 5).

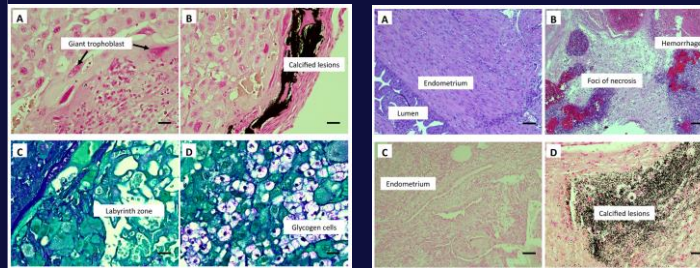


Figure 4: Photomicrograph of placental tissues stained with Von Kossa (A & B) and Periodic Acid Schiff (C & D). Placental tissues from xylene treated rat show calcified lesions (B) with a higher count of glycogen cells (D) compared to control group (A & C). Magnification 40x, scale bar 100µm

Figure 5: Photomicrograph of uterine tissues stained with Hematoxylin & Eosin (A & B) and Von Kossa (C & D). Uterine tissue from xylene treated rat show marked necrosis with calcified lesions (B & D) compared to control (A & C). Magnification 10x, scale bar 100µm

RESULTS

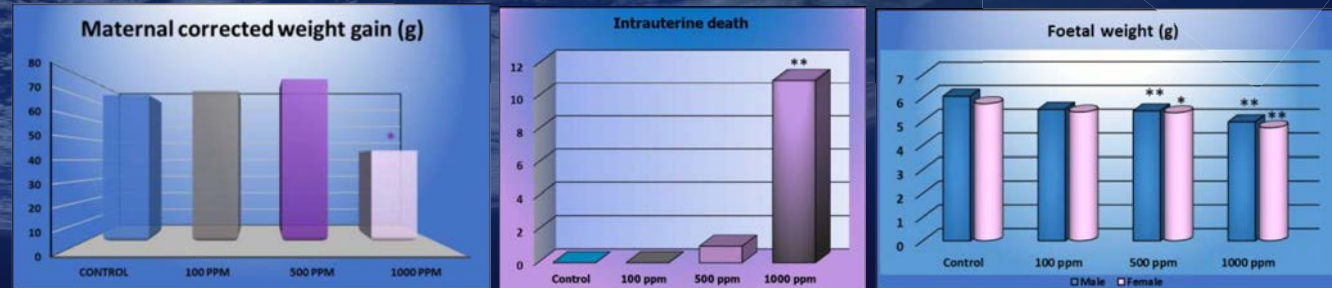


Figure 1

Figure 2

Figure 3

CONCLUSION

Xylene exposure during vulnerable gestational period can adversely affect pregnant rats and foetuses via in-utero inflammatory responses, of which the foeto-placental dynamic was affected. The research findings can be adapted to improve our current guidelines to safeguard maternal and foetal wellbeing during pregnancy.

ACKNOWLEDGEMENT

This work has been supported by Ministry of Higher Education under the Fundamental Research Grant Scheme (FRGS/1/2020/SKK06/UM/03/1)

References

- Bolden, A. L., Kwiatkowski, C. F., & Colborn, T. (2015). New look at BTEX: are ambient levels a problem? *Environmental science & technology*, 49(9), 5261-5276.
- Buesa, R. J. (2007). Histology safety: now and then. *Annals of Diagnostic Pathology*, 11(5), 334-339.
- ICH Harmonised Tripartite. (2005). Detection of toxicity to reproduction for medicinal products & toxicity to male fertility S5 (R2). In: Citeseer.
- Kaneko, T., Wang, P.-Y., Tsukada, H., & Sato, A. (1995). m-Xylene toxicokinetics in phenobarbital-treated rats: comparison among inhalation exposure, oral administration, and intraperitoneal administration. *Toxicology and applied pharmacology*, 131(1), 13-20.
- Saillenfait, A., Gallissot, F., Morel, G., & Bonnet, P. (2003). Developmental toxicities of ethylbenzene, ortho-, meta-, para-xylene and technical xylene in rats following inhalation exposure. *Food and Chemical Toxicology*, 41(3), 415-429.
- World Health Organization. (1984). Principles for Evaluating Health Risks to Progeny Associated with Exposure to Chemicals during Pregnancy-Environmental Health Criteria 30.