*British Journal of Plastic Surgery* (1999), **52**, 6–11
© 1999 The British Association of Plastic Surgeons

BRITISH JOURNAL OF PLASTIC SURGERY

# Scar formation after skin injury to the human foetus in utero or the premature neonate

W. A. Morrison, J. V. Hurley, T. Sarah Ahmad and H. R. Webster

*Bernard O'Brien Institute of Microsurgery and Department of Surgery, St Vincent's Hospital, The University of Melbourne, Melbourne, Australia*

*SUMMARY.* A macroscopically visible scar was present at birth in three infants with a history of injury during amniocentesis at 16–20 weeks' gestation. In several neonates born between 21 and 31 weeks' gestation, chemical injury to the skin caused by extravasation of calcium gluconate healed by formation of a large scar. In the infant born at 21 weeks, biopsy of the injured area showed infiltration by large numbers of neutrophils and macrophages. It appears that a very immature neonate can mount a prominent inflammatory reaction and that both a midtrimester foetus and a very immature neonate heal injuries to the skin by scar formation and not by scarless healing.

**Keywords:** scar, human foetal scarring, neonatal scarring.

In recent years, techniques have been developed which allow successful correction in utero of severe developmental defects in the human foetus.[1] As a consequence, the reaction to injury and mode of repair of foetal tissues, previously of largely academic interest, has acquired great clinical significance. On the basis of earlier studies of wound healing in mice, rats and rabbits, in which the gestation period is only 20–30 days, and in their own experiments in foetal sheep (gestation period 140 days), a group in San Francisco claimed that, except in the late stages of pregnancy, 'the fetus responds to injury in a manner fundamentally different from the adult. Fetal skin healing occurs rapidly and in the absence of scar formation … acute inflammation is virtually absent and collagen is deposited in a highly organised scarless manner.'[2] These claims received much publicity and prompted a search for the factors responsible for 'scarless healing' in the hope that their application might reduce scarring in postnatal wounds.

However, subsequent studies have shown that, given an adequate stimulus, the mammalian foetus from as early as midgestation can both mount a cellular inflammatory reaction and form typical scar tissue.[3–5] The extent of scar formation after foetal injury has been shown to depend upon the animal species, the stage of gestation, the tissue injured and the nature of the wound.[6] In foetal sheep, incised wounds form a scar except in a minority of wounds early in gestation. Larger excised wounds contract and heal by scar. However, similar wounds in foetal rabbits remain unhealed and unaltered until birth and then rapidly heal. In foetal sheep, fractures heal in a similar way to adult fractures[7] and wounds in skeletal muscle,[8] tendon[9] and peripheral nerve[10] all heal by formation of scar tissue. In response to these findings, Longaker and his colleagues have modified their definition of a scar from an abnormal histological collagen pattern,[2] to a macroscopic disturbance assessable no earlier than 1 year after wounding.[6] They have conceded that, even with this modified definition, the earlier claim that 'fetal wounds heal without scarring' is an inaccurate generalisation.

Although it might seem intuitively that healing in the human foetus (gestation 280 days) would resemble more closely the reactions of foetal sheep than small animals such as rats and rabbits, little published evidence is available of the reaction of the human foetus to injury. The present paper reports three cases of intrauterine injury which show that the midgestation human foetus can form a scar after minor damage to the skin. To compare the response of the human foetus to that of a premature neonate of a comparable stage of development, the inflammatory response and mode of healing after chemical or surgical injury to the skin of neonates born at 21–30 weeks' gestation are also described.

## Case reports

### *Injury to the foetus in utero*

Three cases have been seen of recorded intrauterine trauma to a human foetus during the second trimester. Two are based on the obstetrician advising the mother that he had accidentally stabbed the foetus during amniocentesis to exclude foetal abnormality; the third involved deliberate ultrasound-guided transuterine penetration of the foetal abdominal wall for bladder decompression.

### *Case 1*

A 14-year-old girl presented with a webbed scar in the inner canthus of the left eye which was cosmetically embarrassing. Her mother stated that amniocentesis had been performed at 16 weeks' gestation and that the obstetrician had told her at the time that the foetus had been 'pricked' and that blood and tissue had been found on the tip of the instrument when it was withdrawn. After normal vaginal delivery, a reddish scar was

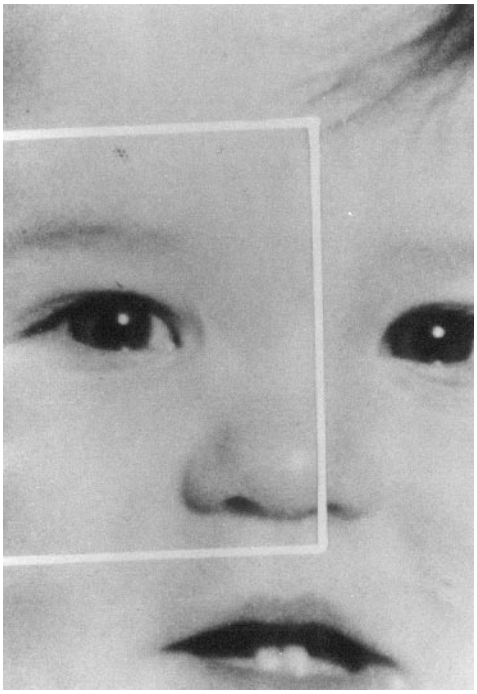

**Figure 1**—Case 1. Photograph at 4 months of age shows scar at inner canthus of right eye. History of injury during amniocentesis at 16 weeks' gestation.

**Figure 2**—Case 1. Appearance of scar at 14 years of age prior to Z plasty.

present at the left inner canthus which the mother was told was a result of the injury 23 weeks earlier. Figure 1 shows the appearance of the scar soon after birth and Figure 2 its appearance at the age of 14 years. Scar revision with Z plasty was performed subsequently to release the webbing. At surgery the tissue was typical of conventional scars, being firm, white and fibrotic.

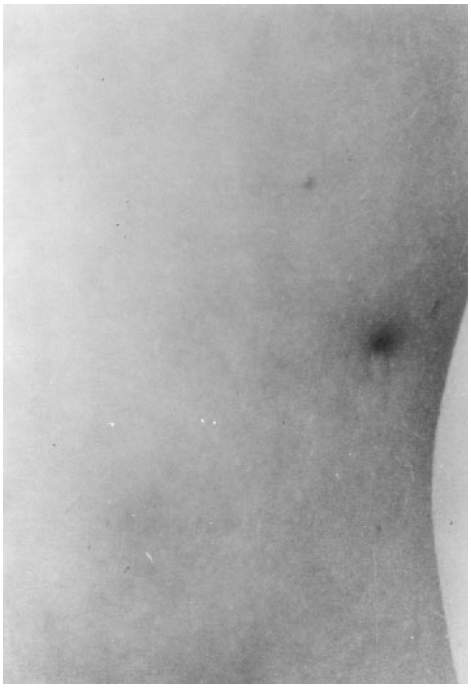

**Figure 3**—Case 2. Dimpled scar on inner aspect of right thigh of 4-year-old boy. History of injury during amniocentesis at 16 weeks' gestation.

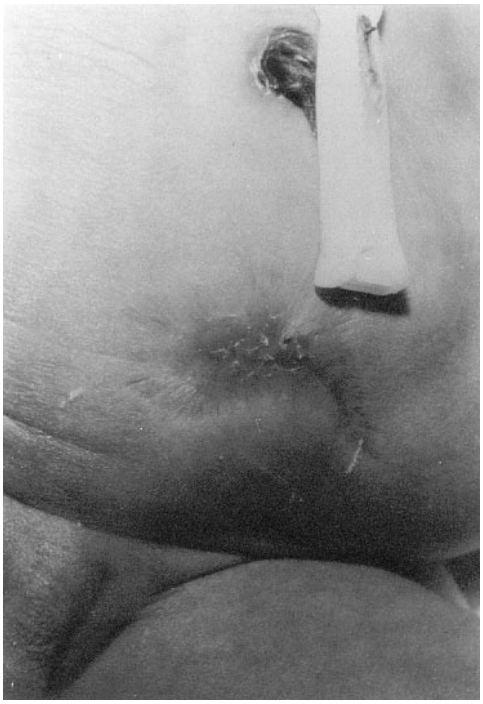

**Figure 4**—Case 3. Stretched scar on abdomen of 4-week post-term baby. History of ultrasound-guided puncture of abdominal wall and bladder for urinary obstruction at 20 weeks' gestation.

*Case 2*

The son of a plastic surgeon had amniocentesis at 16 weeks' gestation and at the time the parents were told that the foetus had been injured with the needle. At birth there was obvious indentation and scarring of the skin on the lateral surface of the right thigh (Fig. 3).

**Figure 5**—Extravasation induced necrosis on dorsum of hand a few days after birth of 26-week neonate.

**Figure 6**—Extensive scarring of injured area 3 years after excision and split skin grafting.

### *Case 3*

A male foetus was diagnosed by ultrasound as having 'prune belly' syndrome. At 20 weeks' gestation under ultrasound control, a transuterine abdominal foetal wall puncture was performed to drain the bladder. Three attempts had to be made before the needle reached the desired position. At birth the baby had a large stretched scar in his abdominal wall (Fig. 4). In all three cases the scars have remained unchanged in appearance during several years' observation.

### *Injury to the premature neonate*

#### *Extravasation injury to the skin*

In neonates ranging in age from 21 weeks' gestation to term, we have seen a number of cases of injury to the skin caused by extravasation of calcium gluconate at a site of intravenous infusion.

Irrespective of the stage of development of the neonate, most cases were treated conservatively and healed spontaneously by a typical adult sequence of eschar, peripheral inflammatory reddening, wound contraction, epithelialisation and scar formation. The larger wounds left significant residual contracture and several required later scar revision for cosmetic reasons.

**Figure 7**—Extravasation induced necrosis of lateral aspect of right ankle of a 21-week neonate.

In two cases, one at 26 weeks' and one at 31 weeks' gestation, split skin autografts were applied to extravasation injuries on the dorsum of the hand (Fig. 5). The grafts healed uneventfully and at follow-up 3 years later, prominent scarring was visible at both the sites of grafting (Fig. 6) and the donor site on the buttock.

In two further cases of 21 and 24 weeks' gestation respectively, maternal skin allografts were applied to extravasation defects in the ankle region (Fig. 7). The grafts took initially but by 12 days had rejected. The 21 week neonate biopsy prior to grafting showed dense inflammatory cell infiltration of the skin, the inflammatory cells being mainly mature polymorphs and a smaller number of macrophages (Figs 8, 9). Three years later a large contracted scar was present at the site of grafting (Fig. 10).

#### *Thoracotomy incisional wound*

A neonate of 26 weeks' gestation underwent thoracotomy for tricuspid incompetence using an intercostal incision. The wound progressed through the standard phases of initial redness to eventual maturation over months to a pale, slightly stretched scar. At 14 weeks it had the appearance typical of a paediatric postnatal wound of similar age (Fig. 11).

## Discussion

The cases described in the present paper establish two important features of the response to injury of the human foetus and neonate. Firstly a minor skin wound in a foetus inflicted as early as 16–20 weeks' gestation may heal leaving a macroscopically visible scar; secondly the response to chemical injury of a neonate

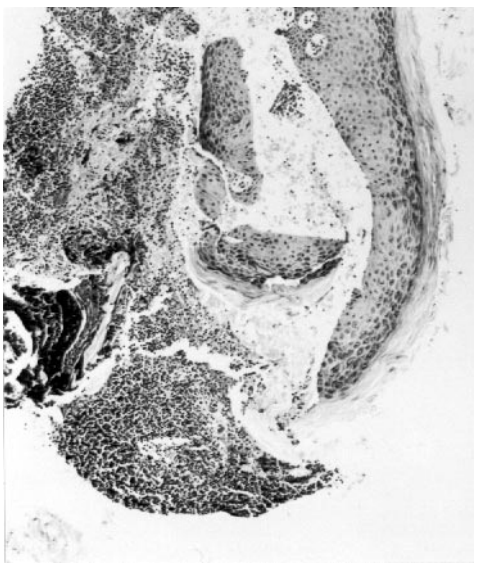

**Figure 8**—Biopsy of edge of area shown in Figure 7 immediately prior to skin grafting shows dense inflammatory cell infiltration in the dermis at the edge of the wound. ×40.

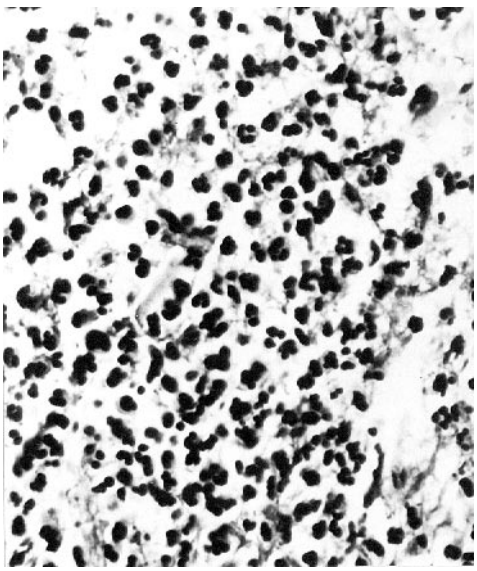

**Figure 9**—Higher magnification of portion of Figure 8. The inflammatory cells are a mixture of neutrophils and macrophages. ×400.

**Figure 10**—Grafted area at 3 years of age shows extensive contracted scar.

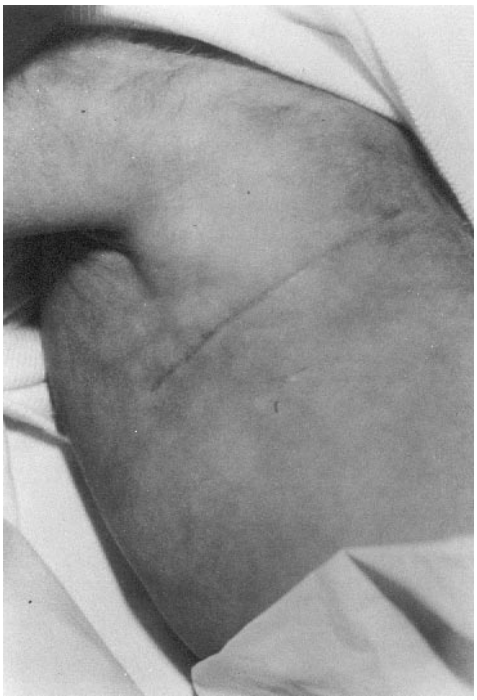

**Figure 11**—26-week premature baby subjected to thoracotomy. Macroscopic appearance of healed incision at 38 weeks shows a scar similar to that expected after similar incision in children or adults.

born as early as 21 weeks' gestation is similar to that of older children and adults, a cellular inflammatory reaction being followed by formation of typical scar tissue. It is convenient to discuss these findings separately.

*Scar formation in the human foetus*

It might be argued that the first two of the three cases of foetal injury described in the present paper are merely anecdotal in that the injury was not directly observed by ultrasound, or other means. If they were an isolated report it would be very difficult to refute this claim. However, a search of the obstetrical literature identified a larger series of similar cases reported almost 20 years ago.[11] At that time, simultaneous amniocentesis and ultrasonic visualisation was not possible and foetal injury during amniocentesis was more common than it is today. In 107 cases of amniocentesis reviewed well after birth, Epley et al reported 10 cases of scarring apparently due to injury during amniocentesis using a 20 gauge needle. Seven cases were 'dimple like' and 2–7 mm in diameter, two were linear and one case had

extensive scarring to the knee after multiple attempts at amniocentesis. Their illustrations show lesions very similar to those described in the present report. In the third foetal case there is no doubt about the authenticity of the injury to the abdominal wall. The procedure was designed to penetrate the foetal abdominal wall to decompress the bladder. This was done successfully and directly observed by ultrasound. The subsequent gross abdominal scarring was at the site of abdominal wall penetration. The San Francisco group has claimed that operative wounds in a human foetus leave no visible scar,[1] but have published no evidence to support this claim. Indeed the findings in one of their unsuccessful cases of repair of a diaphragmatic hernia suggest that after severe injury a human foetus can form abundant scar tissue.[1] A 27-week foetus was delivered 8 days after operation. Two weeks after birth when a Gortex patch was removed from the abdominal wall there was 'dense scarring and extensive bowel damage'. It is hard to believe that such a dense scar developed in 2 weeks – surely the reaction began in utero at the time of the operation.

How do these human findings compare with those reported in foetal sheep? In sutured sheep skin wounds it seems that the initial disposition of collagen fibres has a similar pattern in foetus and adult, and that remodelling to a 'scarless' wound occurs only in the early stages of gestation. All three reports[3,12,13] of excised skin wounds describe rapid healing by wound contraction and granulation tissue formation, and agree that at and beyond 90 days' gestation a collagenous scar is present 14 days after wounding. Burrington[12] described scars at 60 days' gestation and Horne et al[3] at 75 days' gestation. In an abstract, never published in detail, Longaker et al claimed no scar was present at 14 days in a 75-day foetus. The other studies suggest that this was incorrect. Faced with the tissue defect of an implanted sponge, all reports agree that from as early as 75 days' gestation foetal sheep form scar tissue of similar structure and strength to that seen in adult sheep.[3,14] It must be concluded that foetal wounds heal in a similar manner in humans and sheep.

In a series of papers employing a variety of experimental models, the San Francisco group have extended their morphological studies to examine biochemical aspects of foetal wound healing and the role of growth factors in this process. Their findings are summarised in a recent review[6] which concludes that the extent and type of inflammation at the wound site and the resulting profile of growth factors are a major factor in scar formation. This work holds promise of allowing modification of scar formation in both foetal and adult wounds. However it does not alter the morphological findings that minor injury to the skin inflicted early in gestation may lead to scar formation in the human foetus.

*Injury to the premature neonate*

It is well established that in human neonates born at (or close to) term, injury induces a typical inflammatory reaction and surgical and other wounds heal by scar. The cases described in the present paper show a well-developed inflammatory reaction and formation of abundant scar tissue in neonates born as early as 21 weeks' gestation. It is not known whether a foetus-in-utero wound reacts to injury in a similar way.

Studies of wound healing in the opossum, *Monodelphis domestica*, where the foetus is born very immature and spends most of its development in the maternal pouch, indicate that the ability to form scar tissue after injury depends upon the stage of development and the ability to mount an inflammatory response rather than the sterile intrauterine environment.[15] If the same is the case in the developing human, then the reactions of the human foetus would be expected to be similar to those in the very immature neonates described in the present paper. The finding that, from as early as 16 weeks' gestation, relatively minor injuries to the skin inflicted during amniocentesis heal by scar formation supports this hypothesis.

The injury in the neonatal cases described was severe and extensive. Much less severe localised chemical injury to a sheep foetus has been shown to induce a cellular inflammatory reaction from as early as 75 days' gestation[4] and it has been known for many years that intrauterine infection in humans can cause an intense cellular inflammatory response. For example, Barter[16] reported accumulation of both neutrophils and mononuclear cells in the peribronchial tissues in intrauterine pneumonia. Congenital syphilis causes miliary gummata and diffuse fibrosis in the liver and other organs,[17] and listeriosis may cause multiple abscesses in almost any organ of a foetus.[18] Playfair et al[19] found numerous neutrophils in the blood of the human foetus at 20 weeks' gestation and showed that from as early as 16 weeks the foetus can produce a leucocytosis of 5000 cells/mm$^3$ or more. In contrast to these findings Rowlatt[20] reported an absence of both inflammatory response and scar formation following limb amputation and other injuries in a 20 week stillborn foetus. It was suggested that injury was due to amniotic bands but when, and how long before delivery the injuries occurred is not known.

Irrespective of whether injury to a premature neonate induces a similar reaction to that of a foetus at a comparable stage of development, the cases of intrauterine injury described above show that from as early as 16 weeks' gestation, wounds to the skin of a human foetus heal by formation of scar tissue. Intrauterine surgery has a valuable role in the correction of certain severe developmental abnormalities, but it is clearly ill-advised and unjustifiable if undertaken merely in the hope of obtaining smaller or invisible scarring.

**Acknowledgement**

Professor R. McMahon, Department of Paediatrics, Monash University (Case 3) and Mr Graeme Perks (Case 2) kindly allowed us to evaluate their cases. This work was supported by the Royal Australasian College of Surgeons and St Vincent's Hospital.

**References**

1. Harrison MR, Langer JC, Adzick NS, et al. Correction of congenital diaphragmatic hernia in utero. V. Initial clinical experience. J Ped Surg 1990; 25: 47–55.
2. Longaker MT, Adzick NS. The biology of fetal wound healing: a review. Plast Reconstr Surg 1991; 87: 788–98.

3. Horne RSC, Hurley JV, Crowe DM, Ritz M, O'Brien BMcC, Arnold LI. Wound healing in foetal sheep: a histological and electron microscope study. Br J Plast Surg 1992; 45: 333–44.
4. Kumta S, Ritz M, Hurley JV, Crowe D, Romeo R, O'Brien BMcC. Acute inflammation in foetal and adult sheep: the response to subcutaneous injection of turpentine and carrageenan. Br J Plast Surg 1994; 47: 360–8.
5. Hurley JV. Inflammation and repair in the mammalian fetus: a reappraisal. Microsurgery 1994; 15: 811–16.
6. Ferguson MWJ, Whitby DJ, Shah M, Armstrong J, Siebert JW, Longaker MT. Scar formation: the spectral nature of fetal and adult wound repair. Plast Reconstr Surg 1996; 97: 854–60.
7. Slate RK, Posnick JC, Wells MD, Goldstein JA, Keeley FW, Thorner PS. Fetal tibial bone healing in utero: the effects of miniplate fixation. Plast Reconstr Surg 1993; 92: 874–83.
8. Longaker MT, Whitby DJ, Jennings RW, et al. Fetal diaphragmatic wounds heal with scar formation. J Surg Res 1991; 50: 375–85.
9. Al-Qattan MM, Posnick JC, Lin KY, Thorner P. Fetal tendon healing: development of an experimental model. Plast Reconstr Surg 1993; 92: 1155–60.
10. Lin KYK, Posnick JC, Al-Qattan MM, Vassar J, Becker M. An experimental model of fetal nerve healing and regeneration. Surg Forum 1992; 44: 726.
11. Epley SL, Hanson JW, Cruikshank DP. Fetal injury with midtrimester diagnostic amniocentesis. Obstet Gynae 1979; 53: 77–80.
12. Burrington JD. Wound healing in the fetal lamb. J Ped Surg 1971; 6: 523–8.
13. Longaker MT, Burd DAR, Gowan AM, et al. Midgestational excisional fetal lamb wounds contract in utero. J Ped Surg 1991; 26: 942–7.
14. Burd DAR, Longaker MT, Adzick NS, Harrison MR, Ehrlich HP. Foetal wound healing in a large animal model: the deposition of collagen is confirmed. Br J Plast Surg 1990; 43: 571–7.
15. Armstrong JR, Ferguson MWJ. Ontogeny of the skin and the transition from scar-free to scarring phenotype during wound healing in the pouch young of a marsupial, *Monodelphis domestica.* Dev Biol 1995; 169: 242–60.
16. Barter R. The histology of congenital pneumonia: a clinical and experimental study. J Pathol Bacteriol 1953; 66: 407.
17. Anderson JR. In: Muir's Textbook of Pathology, 12th ed. London: Edward Arnold, 1985, 931.
18. Wrigglesworth JH. In: Oxford Textbook of Pathology. McGee JOD, Isaacson PG, Wright NA, ed. Oxford: Oxford University Press, 786.
19. Playfair JHL, Wolfendale M, Kay HEM. The leucocytes of peripheral blood in the immature foetus. Br J Haematol 1963; 9: 336.
20. Rowlatt U. Intrauterine wound healing in a 20 week human fetus. Virchow Arch Path Anat 1979; 381: 353–61.

## The Authors

**W. A. Morrison MD, FRACS**
**J. V. Hurley MD, PhD, FRCPath**
**T. S. Ahmad MB, BS, FRCS**
**H. R. Webster MB, BS, FRACS**

Bernard O'Brien Institute of Microsurgery and Department of Surgery, St Vincent's Hospital, The University of Melbourne, Melbourne, Australia.

Correspondence to W. A. Morrison, Bernard O'Brien Institute of Microsurgery, 42 Fitzroy Street, Fitzroy, Victoria 3065, Australia.

Paper received 6 January 1998.
Accepted 18 September 1998, after revision.