



## CLINICAL CASE REPORT

# Electroacupuncture-Assisted Craniotomy on an Awake Patient



Amritpal Sidhu<sup>1,\*</sup>, Trushna Murgahayah<sup>2</sup>, Vairavan Narayanan<sup>1</sup>,  
Hari Chandran<sup>1</sup>, Vicknes Waran<sup>1</sup>

<sup>1</sup> *University Malaya, Faculty of Medicine, Jalan University, Kuala Lumpur, Malaysia*

<sup>2</sup> *Hospital Raja Permaisuri Bainun, Jalan Hospital, Perak, Malaysia*

Available online 15 September 2016

Received: May 3, 2016  
Revised: Jun 18, 2016  
Accepted: Jun 27, 2016

### KEYWORDS

acupuncture;  
awake craniotomy;  
neurosurgery

### Abstract

Although acupuncture has existed for over 2000 years, its application as an anesthetic aid began in the 1950s in China. The first surgical procedure performed under acupuncture anesthesia was a tonsillectomy. Soon thereafter, major and minor surgical procedures took place with electroacupuncture alone providing the anesthesia. The procedures performed were diverse, ranging from cardiothoracic surgery to dental extractions. Usage of acupuncture anesthesia, specifically in neurosurgery, has been well documented in hospitals across China, especially in Beijing, dating back to the 1970s. We present a case of a 65-year-old man who presented with right-sided body weakness. He had a past medical history of uncontrolled diabetes mellitus, hypertension, and obstructive sleep apnea requiring use of a nasal continuous positive airway pressure device during sleep. We performed a computed tomography brain scan, which revealed a left-sided acute on chronic subdural hemorrhage. Due to his multiple comorbidities, we decided to perform the surgical procedure under electroacupuncture anesthesia. The aim of this case report is to describe a craniotomy performed under electroacupuncture on an elderly patient with multiple comorbidities who was awake during the procedure and in whom this procedure, if it had been performed under general anesthesia, would have carried high risk.

This is an Open Access article distributed under the terms of the Creative Commons Attribution Non-Commercial License (<http://creativecommons.org/licenses/by-nc/4.0>) which permits unrestricted non-commercial use, distribution, and reproduction in any medium, provided the original work is properly cited.

\* Corresponding author. Department of Surgery, Faculty of Medicine, University of Malaya, Jalan University, 59100, Kuala Lumpur, Malaysia.

E-mail: [amritpalssidhu@yahoo.com](mailto:amritpalssidhu@yahoo.com) (A. Sidhu).

pISSN 2005-2901 eISSN 2093-8152

<http://dx.doi.org/10.1016/j.jams.2016.06.005>

Copyright © 2016, Medical Association of Pharmacopuncture Institute. Publishing services by Elsevier B.V.

## 1. Introduction

Although acupuncture has existed for over 2000 years, its application as an anesthetic aid began in the 1950s in China [1]. Electroacupuncture is believed to have been first used in France and Italy as far back as the 19<sup>th</sup> century [2]. Currently, it is an increasingly popular form of treatment and is used by practitioners of traditional Chinese medication for a wide array of conditions. Electroacupuncture involves the insertion of thin, sterile needles into specific trigger points at anatomical locations on the body that are associated with neural and vascular structures [3]. Stimulations of these structures through stimulations at the anatomical locations then influence various neurophysiologic processes.

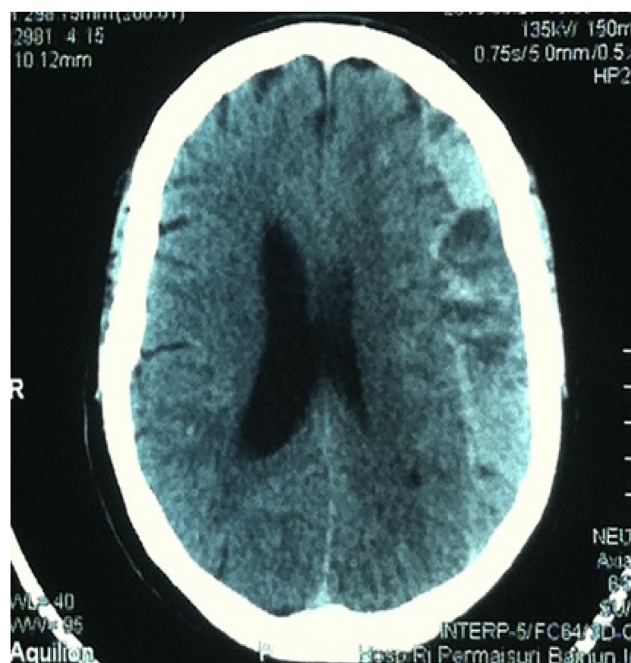
Several theories have been presented to explain how electroacupuncture works [4]. One such theory is that electroacupuncture stimulation causes an increase in the levels of endorphins in several parts of the central nervous system, which, in turn, inhibits the transmission of pain signals because that is a principal function of endorphins. Another is the gate theory proposed by Melzack [7], which hypothesizes that painful excitation is transmitted in a gelatinous substance within the spinal cord through thin nerve fibers and that acupuncture stimulates the thick myelinated fibers that have an inhibitory effect on pain by closing the gate at the spinal level. This, therefore, inhibits the transmission of pain via the thin nerve fibers.

The analgesia effect afforded by acupuncture, especially electroacupuncture [5], can be so profound that it has, at times, been used as the sole pain-relieving measure during surgery. If acupuncture anesthesia is used in combination with an anesthesia drug, a lower dosage of the anesthetic drug can have the desired effect. The aim of this report is to describe how electroacupuncture can be used as a viable option in the surgical treatment of patients for whom the use of general anesthesia would carry a higher risk.

## 2. Case presentation

A 65-year-old man presented with a gradual onset of right-sided body weakness, which had been associated with headache during the previous 2 weeks. On further questioning, he revealed that he had had a trivial fall 2 weeks prior to presentation. On presentation, his vital signs were stable. His Glasgow Coma Scale was 15/15. Pupils were 2 mm bilaterally. The neurological examination revealed a right-sided upper and lower limb weakness with muscle power of 3/5. He had a past medical history of obstructive sleep apnea, which required that he use a nasal continuous positive airway pressure device during sleep. He also had uncontrolled diabetes mellitus and hypertension. A computed tomography brain scan was done and revealed a left-sided acute-on-chronic subdural hemorrhage (Fig. 1).

Due to the patient's multiple comorbidities and the risk of general anesthesia, the patient received counsel from the anesthesiologist and the neurosurgeons. As acupuncture is a viable anesthesia option at our center for patients that have increased risk if they undergo surgery under general anesthesia, he was given the option of using electroacupuncture solely during the surgery. After careful consideration, the patient agreed to undergo a craniotomy



**Figure 1** Computed tomography scan showing left acute or chronic subdural bleeding.

under electroacupuncture while awake and provided full, informed, written consent for the use of electroacupuncture instead of general anesthesia. The patient also consented to the publication of this case report and the use of figures showing his surgery. The Ethics Committee at our Center approved the protocol of this study.

The operative procedure for the craniotomy performed under electroacupuncture was as follows: firstly, the patient was taken into the operation theater and placed in the supine position. Acupuncture points GB-3, GB-14, GB-19, and GB-20 were used, and acupuncture needles with a 0.25 mm diameter and a 40 mm length were inserted under aseptic conditions (Fig. 2).

Next, the needles were attached to an electronic acupuncture treatment instrument (Hwato 6-channel Needle Stimulator; Fig. 3). The patient's scalp incision was marked. Then, the operative field was cleaned and draped. The device was set at a frequency of 50 Hz, a pulse duration of 50 ms, and an intensity of 12 mA. Second was the surgical procedure (Fig. 4). Prior to the incision, local anesthesia with lignocaine was used only to infiltrate the skin (lignocaine 2 mg/kg). The skin was incised with an 11 blade right up to the periosteum. Next, the periosteum was separated, and the craniotomy was performed. The dural layer was incised, and the underlying blood clot removed. After irrigation and adequate hemostasis, the dura was apposed and the bone re-anchored. Finally, the galea and skin were sutured.

No general anesthesia was used throughout the surgery. The operation took about 1 hour, and the electroacupuncture stimulation was terminated once the skin had been closed. Overall, the patient tolerated the procedure well. He did not complain of any pain throughout his surgery; neither did he complain of any immediate complications such as nausea or vomiting. Postoperatively, the patient recovered without complications. A repeat

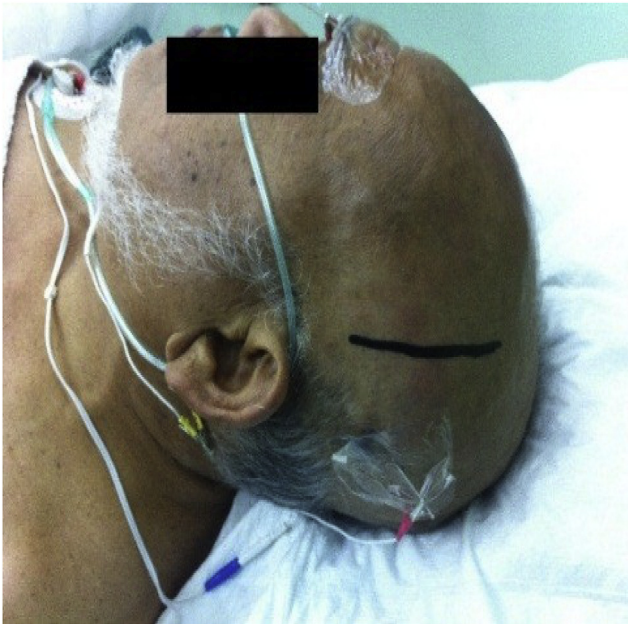

Figure 2 Acupuncture needles *in situ* preoperatively.

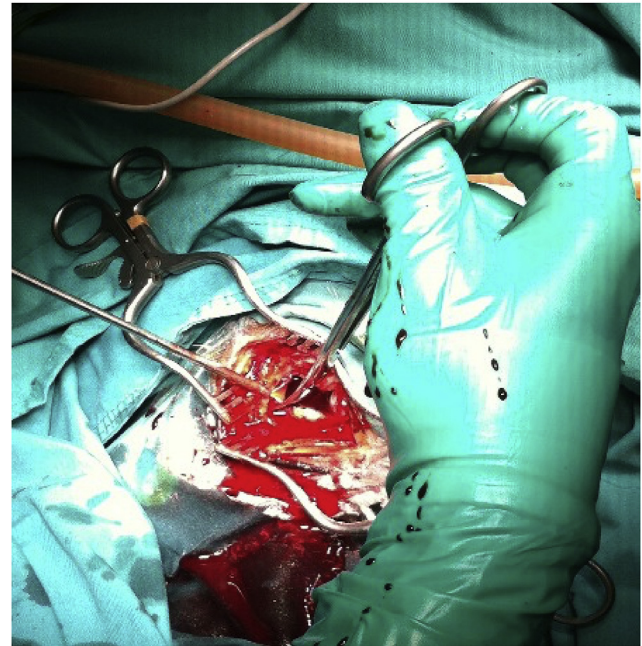


Figure 4 Intraoperative evacuation of blood clots.



Figure 3 Electroacupuncture device used.

computed tomography brain scan postoperatively showed near complete evacuation of the subdural hemorrhage. The patient, who was satisfied with the overall procedure, was discharged without incident on postoperative Day 2.

### 3. Discussion

Electroacupuncture-assisted anesthesia works for a wide range of surgical procedures. It not only plays an important role during the perioperative and the recovery periods by reducing the need for gas and other anesthesia drugs

intraoperatively but also helps in easing the emergence from anesthesia and facilitating recovery following the procedure [6]. Electroacupuncture is beneficial as it does not produce any of the side effects that are so often seen when drugs are used for anesthesia. Electroacupuncture is especially suitable for elderly patients or for patients who are allergic to or, for some reason, unable to tolerate drugs. Furthermore, electroacupuncture is suitable for patients with multiple comorbidities for whom undergoing surgery under general anesthesia carries a higher risk. This was clearly the case for our patient, as evidenced in the case reported presented above.

The application of electroacupuncture in neurosurgery specifically is very useful because it avoids the use of drugs that interfere with the autoregulation of cerebral circulation and the reactivity to the arterial concentration of carbon dioxide, which then affects cerebral vasodilatation and intracranial pressure. Such effects of electroacupuncture surely provide an environment that is more conducive for surgery. Furthermore, electroacupuncture also allows the patient to be awake during surgical intervention while maintaining analgesia. This is important, taking into account the fact that in neurosurgery, a craniotomy with the patient awake is becoming increasingly popular as an approach to surgery performed on the motor and speech areas, particularly in epilepsy surgery and deep brain stimulation surgeries. Postoperatively, electroacupuncture also provides a great advantage by allowing rapid postoperative awakening. This is particularly important in neurosurgery as an immediate postoperative neurological evaluation can be made.

As electroacupuncture-assisted anesthesia is an emerging field and craniotomies with the patient awake are highly desirable for a neurosurgeon, further work should be carried out in this area because electroacupuncture-assisted surgeries may be a viable option in the near future. Our



experience supports the use of electroacupuncture-assisted anesthesia in craniotomies for patients with high risk if they undergo surgery under general anesthesia.

#### 4. Conclusion

Electroacupuncture is clearly beneficial during the intra- and postoperative stages of surgery. This is more so in neurosurgery where the choice of the anesthetic substances must take into account the effects they have on the cerebral substance. We, therefore, support the idea that using as few drugs as possible eliminates the shortcomings associated with their use and improves the intraoperative environment, as well as the outcome of the surgical intervention. For these reasons, we used electroacupuncture as the anesthetic method of choice in the above case, where the risk to the patient of surgery under general anesthesia was great. We hope that in the near future, the best surgical techniques and medical experiences of both Eastern and Western medicine can be combined to maximize the benefit to and the safety of all patients.

#### Disclosure statement

The authors declare that they have no conflicts of interest and no financial interests related to the material of this manuscript.

#### Acknowledgments

We would like to thank the operation theatre staff and anesthesiologist involved in this procedure. Amritpal Sidhu, Trushna Murgahayah, and Hari Chandran were involved in the patient care and surgical procedure. Vicknes Waran and Vairavan Narayanan were involved in the literature review and manuscript preparation.

#### References

- [1] Bonica JJ. Acupuncture anesthesia in the People's Republic of China: implications for American medicine. *JAMA*. 1974;229:1317–1325.
- [2] Helms JM. An overview of medical acupuncture. Redondo Beach, CA: American Academy of Medical Acupuncture.
- [3] Shaozong C. Modern acupuncture theory and its clinical application (Chapter 5: The morphological relationship between points and nerves). *Int J Clin Acupunct*. 2001;12:149–158.
- [4] Pomeranz B. Scientific research into acupuncture for the relief of pain. *J Altern Compl Med*. 1996;2:53–60.
- [5] Xiao-Hong C, Guo SF, Chang CG, Han JS. Optimal conditions for eliciting maximal electroacupuncture analgesia with dense-and-disperse mode stimulation. *Am J Acupunct*. 1994;22:47–53.
- [6] Liu WC. Acupuncture anesthesia: a case report. *JAMA*. 1972;221:87–88.
- [7] Melzack R, Wall PD. Pain mechanisms: a new theory. *Science*. 1965;150(3699):971–979.